

カテゴリー：エンド

キーワード：バイパス 歯内治療の偶発症 レッジ

## レッジ形成（歯内療法における大きな課題）のレビュー

英文：Ledge Formation: Review of a Great Challenge in Endodontics

Hamid Jafarzadeh, DDS, MSc and Paul V. Abbott, BDS, MDS, FRACDS

*J Endod.* 2007;33(10):1155-1162.

### 目 的

レッジの病因、関連因子、認識、予防、予後、および歯内療法における重要な考慮事項について述べることを目的とする。

### 病因・原因

レッジは、以下のような歯内療法の際には、様々なエラーによって引き起こされる場合がある。

- (1) アクセスキャビティを十分に拡張せず、根尖部分に十分なアクセスができない
- (2) 隣接した面の空洞や隣接した修復物をあたる状態で歯内療法を行おうとすると、器具の制御が完全に失われる（髄腔内壁や修復物除去をせず器具を挿入すると器具の動きが制御される）
- (3) 根管方向の不適切な評価
- (4) 誤った作業長の決定
- (5) 器具を無理に根管に押し込んだ場合
- (6) 湾曲した根管にプレーカーブのないステンレス製の器具を使用した場合
- (7) 順序通りに器具を使用しない場合
- (8) 作業長でファイルを回転させる（つまりリーミング動作の過剰使用）
- (9) 器具使用時の洗浄や潤滑が不十分である場合
- (10) キレート剤に過度に依存している場合
- (11) 破損した器具の除去時
- (12) 歯内再治療時の根管充填材を除去時
- (13) 石灰化した根管を形成しようとした場合
- (14) 根管形成時に誤って根尖部の切削片を押し込む

**病因・原因**

- ・器具の使用法、根管の曲率、歯の種類、根管の位置などの要因が、すべてレジジ形成に関連すると考えられている。(表1および2)。
- ・特に根管の曲率が20°以上になるとレジジが著しく増加した。
- ・術者の熟練度にも関連している。(学生に治療された根管の52%にレジジが発生したが、歯内療法専門医が行なった未処置根管に治療を行った場合33%であった)

**TABLE 1. Summary of Factors Reported to be Associated with Ledge Formation**

Author(s)/year	Factors evaluated	Results	Tooth type	Sample size	Method of study
Bergenholtz et al, 1979 (14)	Reason for endodontic retreatment	Technical reasons have higher possibility of ledge formation than presence of periapical pathosis	All teeth	660	Clinical and radiographic re-examination, 2 years after endodontic retreatment
Stadler et al, 1986 (15)	Instrumentation technique	Reaming technique has more important effect in comparison with filing technique	Roots with various degrees of curvature	520	Clinical study of treatment by supervised dental students
	Root canal curvature	Significant variable (curvature $\geq 35$ degrees has main effect on incidence)			
Greene and Kreil, 1990 (7)	Tooth number Canal location Working length Master apical file size Root canal curvature	Significant variable Significant variable Insignificant variable Insignificant variable Most significant variable (curvature $\geq 20$ degrees has main effect on incidence)	Maxillary and mandibular molars	171	Radiographic examination of cases treated by third-year dental students
Nagy et al, 1997 (3)	Root canal morphology	Insignificant variable	Extracted roots (straight, apically curved, or entirely curved canals)	420	Superimposition of buccolingual and mesiodistal radiographs before and after canal preparation
Kapalas and Lambrianidis, 2000 (4)	Undergraduate students	Canal location	Significant variable (MB, ML, and DB canals have higher frequency than D and P canals)	141	Evaluation based on angled working length radiographs, master cone radiographs, and final radiographs
	Canal curvature	Most significant variable			
	Tooth number	Insignificant variable (but mandibular left 2nd molar had highest incidence)			
	Endodontists (treatment cases)	Canal location	Significant variable (MB and DB canals have highest incidence)	78	
	Endodontists (retreatment cases)	Canal curvature	Most significant variable		
		Tooth number	Insignificant variable		
		Canal location	Insignificant variable		
		Canal curvature	Most significant variable		
		Tooth number	Significant variable		
Eleftheriadis and Lambrianidis, 2005 (16)	Tooth type	Significant variable (higher prevalence in molars than in anterior teeth or premolars)	140 anterior teeth, 156 premolars, 92 molars	388	Evaluation of postoperative radiographs from patient records
	Molar location	Insignificant variable (but mandibular left 2nd molar exhibited highest incidence)			
	Canal location (in molars)	Significant variable (MB, ML, and DB canals have highest incidence)			
	Root canal curvature	Most significant variable			

D, distal; DB, distobuccal; MB, mesiobuccal; ML, mesiolingual; P, palatal.

表 1. レジジ形成に関連すると報告されている要因のまとめ

**TABLE 2. Comparison of Instrumentation Techniques and Their Relationships to Ledge Formation: Summary of Reported Studies**

Author(s)/year	File systems/ techniques examined	Type of canal/teeth	Highest incidence of ledge formation	Lowest incidence of ledge formation	Sample size	Incidence of ledge formation	Method of study
McKendry et al, 1988 (17)	K-Flex and Flex-R files	Molars	K-Flex file	Flex-R file	127	K-Flex (37%) Flex-R (21%)	Radiographic evaluation by 2 endodontists
Zmerner and Marroero, 1992 (18)	Tri-files, Flex-R files, Flexofiles, and K-files	Curved root canals of extracted single-rooted teeth	Flexofile and conventional K-files	Tri-file and Flex-R files	80	0% (Tri-files & Flex-R) 10% (Flexofile) 30% (K-file)	Scanning electron microscope
Nagy et al, 1997 (3)	Traditional and flexible hand instruments, 3 different engine-driven instruments, sonic and ultrasonic instruments	Extracted human teeth in 3 groups (straight canals, apical curve, and curves along entire length of root)	Not stated	Not stated	420	Not stated	Superimposition of buccolingual and mesiodistal radiographs before and after canal preparation
Kapalas and Lambrianidis, 2000 (4)	Step-back technique	Mandibular and maxillary molars	—	—	367* 259†	52%* 33%† (treatment) 41%† (retreatment)	Evaluation based on angled working length radiographs, master cone radiographs, and final radiographs
Namazikah et al, 2000 (6)	SS K-files and Rotary NiTi 0.04 taper files	Extracted maxillary and mandibular first molars	SS K-files	Rotary 0.04 taper files	196	Not stated	Examination of preoperative and postoperative radiographs by postgraduate endodontic students
Calberson et al, 2002 (19)	GT rotary files	Simulated resin root canals with 40- and 60-degree curvature	—	—	38	2.6%	Image superimposition and analysis of preoperative and postoperative pictures
Xu et al, 2004 (20)	ProTaper rotary system and hand files step-back technique	Teeth with curved root canals	Hand files step-back technique	ProTaper	68	0% (ProTaper) 5.8% (hand technique)	Analysis with radiographs before, during, and after operation
Xu et al, 2005 (21)	Profile, ProTaper, and Hero 642 rotary systems	Teeth with curved root canals	—	—	80	0%	Analysis with radiographs before, during, and after operation
Xu et al, 2005 (22)	Hero 642 rotary system and hand files step-back technique	Molars	Hand files step-back technique	Hero 642	60	0% (Hero 642)	Radiographs before and after treatment
Yoshimine et al, 2005 (23)	ProTaper, K3, and Race rotary systems	Simulated S-shaped canals in clear resin blocks	ProTaper	K3 and RaCe	30	Not stated	Comparison of preoperative and postoperative images under stereomicroscope
Jahan et al, 2006 (24)	Er:Cr:YSGG laser and conventional canal preparation	Extracted human permanent mandibular molars (straight and curved roots)	No difference	No difference	40	Not stated	Morphologic study

\*Root canals prepared by students.

†Root canals prepared by endodontists.

表 2. 器具操作の比較とレジジ形成との関係。報告された研究の概要

## 認 識

- ・ レッジを認識することは、レッジに対する処置の第一歩である。
- ・ 臨床的または X 線的な観察によって行われる。
- ・ レッジが形成されると、通常、その時点で根管はストレートになりファイルがカーブを通過しなくなり、そこで止まってしまう。
- ・ レッジの形成が疑われる場合には、歯の X 線写真で、ファイルをレッジの疑いのある位置に置いて撮影する。X 線写真で、器具の先端が根管内から離れていることが確認された場合には、レッジが存在する可能性が高い。
- ・ 既存の根管充填物を除去して歯内療法を行う必要がある症例では、既存の根管充填物が理想的な作業長よりも 1mm 以上短い場合や、根管が大きく曲がっている歯では特に、根管の経路から逸脱した位置に充填物が装着されているように見える場合には、レッジの存在の可能性を考慮すべきである。

## 予 防

- ・ 術者がインスツルメンテーションの過程で注意深く注意を払っていれば、レッジが発生する可能性は最小限に抑えられる。
- ・ 術前の正確な X 線写真と根管長を決定するための「作業用」X 線写真の使用、大量の洗浄、プレカーブファイル、および段階的な器具の使用は、すべてレッジ形成が起こる可能性を大幅に減少させる。

### 術前評価

- ・ レッジ形成の予防は、術前に撮影した X 線写真の曲率、根管長、根管の太さを徹底的に調べることから始まる。
- ・ X 線写真における診断は、治療を開始する前、および最初の器具を根管内に設置する前に完了する必要がある。
- ・ 典型的な根管の形態とその変化についての知識と認識は、歯内治療中、特に器具操作の際には常に必要である。

### 技術的手順

ここ数年、歯内治療のテクニックや器具のデザイン、器具の製造に使用される金属の種類が急速かつ大幅に変化し、根管形成のエラーを予防の方向に向かっている。

### アクセスキャビティの形成と作業長の決定

- ・ 洗浄・形成の前に作業長を決定することは、アクセスキャビティの形成である。

- ・理想的な長さよりも短い根管形成はレッジ形成の前兆となるため、ワーキングレングスを正確に測定する。
- ・根管歯冠側が大きく湾曲していると、レッジ形成の原因となる。ストレートラインアクセス、根管口のフレアー形成を行うことで、根尖 1/3 へのアクセスができる。
- ・長い根管や直径の小さい根管は、短い根管や直径の大きい根管に比べてレッジが起こりやすい。レッジの形成を防ぐためには、根管経路の維持に細心の注意を払う必要がある。

### 灌漑/潤滑/キレート剤

- ・根管器具使用の際には、潤滑剤の使用に加えて、頻繁な洗浄と排出が必須である。
- ・次亜塩素酸ナトリウムは、出血の抑制、抗菌作用、潤滑、および有機物の除去のため使用される。
- ・シリコーン、グリセリン、およびワックスペースの潤滑剤が、ファイルと根管壁の潤滑のために使用される。潤滑性を高めることで、ファイルの挿入が容易になり、ファイルへのストレスが軽減され、デブリの除去が可能になる。
- ・EDTA のようなキレート剤は、湾曲根管を通過しようとするときには慎重に使用すべきである。これらの薬剤は象牙質の壁を軟化させるため、過剰な器具操作を行うとレッジ形成の原因となる。

### 器具操作 (ファイル操作)

- ・パッシブステップバック法とバランスド・フォース法は、レッジ形成の可能性を減少させる有益な 2 つの根管形成法である。
- ・ステップバックテクニックの利点は、この方法が移動やレッジ形成などの処置上のエラーを最小限に抑える。
- ・各ファイルは、より大きなサイズを使用する前に、緩くなるまで根管内で作業しなければならない。
- ・ファイルは順番に使用し、根管内で過度にバインドしないようにしなければならない。
- ・バインドが見られた場合、術者はすぐに小さいサイズのファイルに戻し、大きなサイズの器具を使用した際にできた凹凸や段差を取り除くために円周ファイリングを行う。
- ・円周ファイリングを効果的に行うことで、歯管壁が滑らかになり、歯管の冠端に向かってフレアーが形成され、レッジの形成を防ぐことができる。
- ・ファイルをプレカーブさせ、無理に押し込まないようにすることは、レッジ形成を予防する上で最も重要であり、リーミング操作はしない。
- ・根管の曲率を維持するには、先端がノンカッティングチップの器具や NiTi ファイルの使用が非常に有効であることが示されている。

## 器具の改良

- ・フレキシブルファイル（NiTi ファイルなど）の使用によるレッジ形成の発生率は、従来のハンドステンレス K タイプファイルを使用した場合よりも低い。
- ・ Flex-R ファイル等のように、ファイルの先端がノンカッティング及び円錐形状のファイルは、根管壁に食い込まず、根管壁に追従しやすい（図 2）。
- ・ C ファイル（Dentsply/Maillefer, John-son City, TN）がある。C ファイルは、K ファイルに比べて耐屈曲性が強いため、根管口部の位置がわかりやすく、根尖 3 分の 1 へのアクセスが容易である。また、先端がピラミッド状になっているため、根管内のネゴシエーション時に挿入しやすく、断面が四角いため、歪みにくい。
- ・ 10 番のファイルから 15 番のファイルに進めることが非常に困難なタイトなカーブの根管では、中間ファイルを使用する。

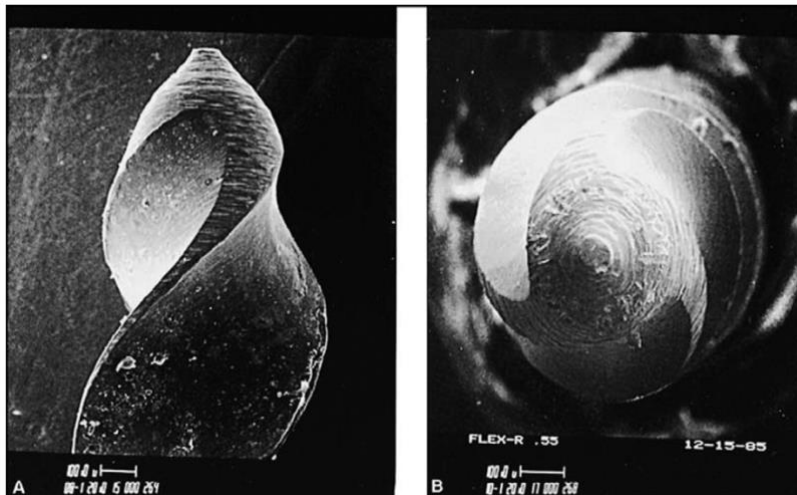


図 2. 先端がノンカッティングの Flex-R-file。

A) 丸みを帯びた先端部。

B) ノンカットチップの「エンドオン」または「ノーズ」ビューでは、その形状が示されており、これにより根管壁のえぐりが少なくなり、レッジ形成が発生しにくくなる。

INGLE JI, Bakland LK.からの許可を得て転載 Endodontics. 5th ed. London: B.C.

Decker Inc, 2002; 483.1

## 対処法

- ・レッジを修正するには、処置上の事故の程度に応じて、方法がある。

- ・理想的な作業長に再ネゴシエーションできたとしても、レッジをバイパスしたり除去したりすることは困難である。場合によっては、管をまっすぐにした際に根の湾曲部の凹面に「ストリップパーフォレーション」が発生することがある。
- ・25番や30番のファイルで形成されたレッジは、小さいファイルで形成されたレッジよりもはるかに回避が困難である。
- ・早期に認識することで、このようなレッジの対処が容易になる。

### 根管探索／レッジの回避

- ・作業長に達する最も短いファイルを選択する。短いファイルは剛性が高く、臨床家の指を器具の先端に近づけることができるので、触覚が大きくなり、器具のコントロールがしやすくなる。
- ・本来の根管はレッジを含む部位から、大きく湾曲している為、最初は先端（つまり先端2～3mm）が明確にカーブしている小さなファイル（10番や15番など）（図3）を使用して、根尖孔までの根管を探る。
- ・湾曲したファイル先端は、レッジと反対側の壁に向けておく。ファイルをわずかに回転させ、「ピッキング」動作を組み合わせることで、器具を前進させ、根管の作業長まで滑らせる。ファイルに抵抗を感じ、進まない場合は、ファイルをわずかに歯冠側に後退させ、ファイルの先端が別の方向に向け、再び前進させる。この動作を、ファイルがレッジを通過するまで繰り返す。
- ・うまくいかない場合、術者は十分な洗浄を行ってレッジに隣接する根管をあらかじめ拡張し、ファイルをわずかに強くプレカーブさせてレッジを迂回させ、根管の作業長まで探索する。
- ・レッジを回避できたならば、#15のファイルが作業長に達するまで拡大する。

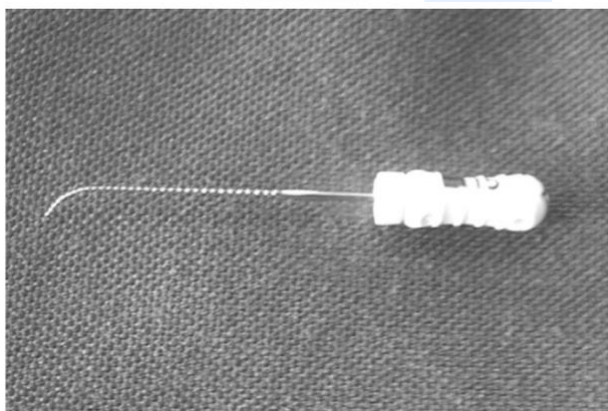


図3. ファイルの先端に明確なカーブがある（プレカーブのあるファイル）

### レッジを回避した後の処置（根管形成・拡大）

- ・探索ファイルを作業長まで到達することができたら、**apex locator** を用いて根尖に到達したかどうかを判断し、作業長を確認するために X 線写真を撮影するとよい。
- ・後続のファイルは、根管の作業長に合わせて、探索用ファイルと同様の方法で使用し、根尖孔に到達するまでの道筋を維持する必要がある。

### 推奨事項 1

- ・ファイルの先端をレッジから根尖の方向に配置できたら、根尖にとどまることに重点を置いて、ファイリングの動きや時には非常に短いプッシュプルの動きで根管内を出入りさせる（図 1、B-D）。
- ・潤滑剤を使用し、頻繁に洗浄して象牙質の破片を除去することで、閉塞を防ぐ。
- ・通常レッジは、根管湾曲部位の外側に位置するため、ファイルを根管壁に押し付けながら、短いストロークでファイルを動かすと、レッジのエッジを除去する。
- ・ファイルが自由に動く場合は、やや長めのプッシュ・プルストロークでレッジのサイズを小さくする。
- ・ファイルが根管内で容易に滑る場合は、引き抜く際にファイルを時計回りに回転させるべきである（バランスドフォーステクニク）。この動作により、ステンレススチールファイルの先端 1/3 がまっすぐになる動きでレッジ部分を削り取り、除去する。

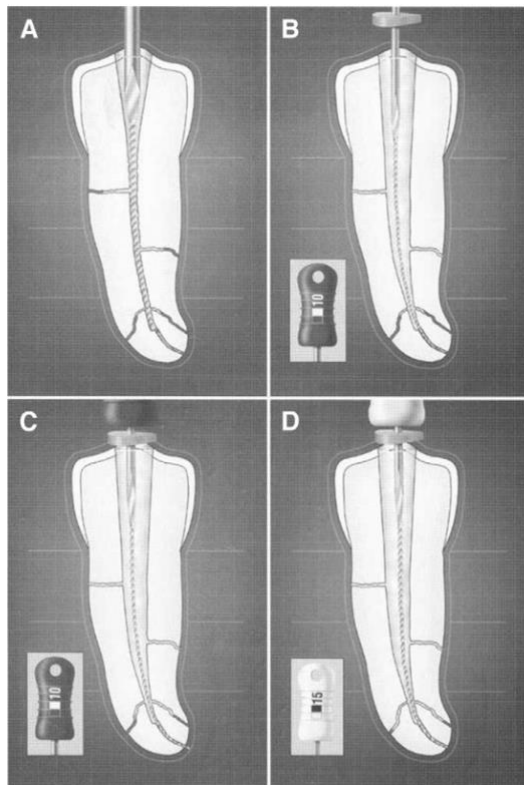


図 1. A) バイディングしており、ファイルの先端は根管湾曲に追従していない。  
B) 歯冠部の 3 分の 2 を拡張し、10 番のプレカーブファイルでレッジをバイパスしているが、まだ歯冠部の長さに達していない。  
C) レッジがバイパスされ、10 番ファイルで管の全長までネゴシエートされている。  
D) 15 番のファイルを使用してレッジをバイパスし、作業長までネゴシエートしている。  
Cohen S, Burns RC からの許可を得て Pathways of the Pulp. 8th ed. セントルイス、ミズーリ州: 2002;913.2

## 推奨事項 2

- ・レッジを除去する器具として、Greater Taper (GT) NiTi hand files (Dentsply/Tulsa Dental) (テーパーの大きい手用 NiTi ファイル) を使用する。
- ・GT ハンドファイルは、先端径が 0.20mm、最大フルート径が 1.00mm で、そのテーパーが従来の 0.02 テーパーファイルの 3~6 倍であることである。GT ハンドピース 1 本には、最大で ISO テーパーファイルの 13 倍に相当する。
- ・#20 の手用 SS ファイルを使用して根管をネゴシエートし、「パイロットホール」または「パスウェイ」が形成する。手用 GT ファイルの先端部を、レッジを越えて移動させるため、ファイルベンダープライヤーを用いて器具をプレカーブさせる (図 4 の A)。手用 NiTi ファイルのプレカーブの方法は、まず手用 GT ファイルのワーキングエンドをファイルベンダープライヤーでしっかりとつかみ、次にハンドルを 180~270 度の曲げる。
- ・手用 GT ファイルは、大きなファイルから小さなファイルへと使用する。適切な先細りの手用 GT ファイルは、ラバーストッパーの向きを変えて管内に挿入し、器具の先端がレッジを迂回して根尖に運ぶ (図 4、B)。
- ・根管の形態に応じて、この GT ハンドファイルを歯管全長に渡って使用するか、より小さなテーパーのついた GT ハンドファイルを選択し (図 4、C)、バランスドフォーステック方法で使用する。手用 GT ハンドファイルを使用した後、No.10 または No.15 の SS ファイルを根管内に挿入し、レッジが減少または消失したかどうかを確認する。

最終的に術者は、術前のレントゲン写真や歯根の大きさを確認する。レッジを完全に除去を目指して形成処置を続けるか、あるいは過剰な形成で歯根の脆弱化や穿孔の危険性を判断した場合には処置を中止するかを決定しなければならない。

術者は、すべてのレッジを除去できるわけではなく、また、除去すべきでもないことを念頭に置き、リスクとベネフィットを評価しながら、可能な限り象牙質を残す努力する。



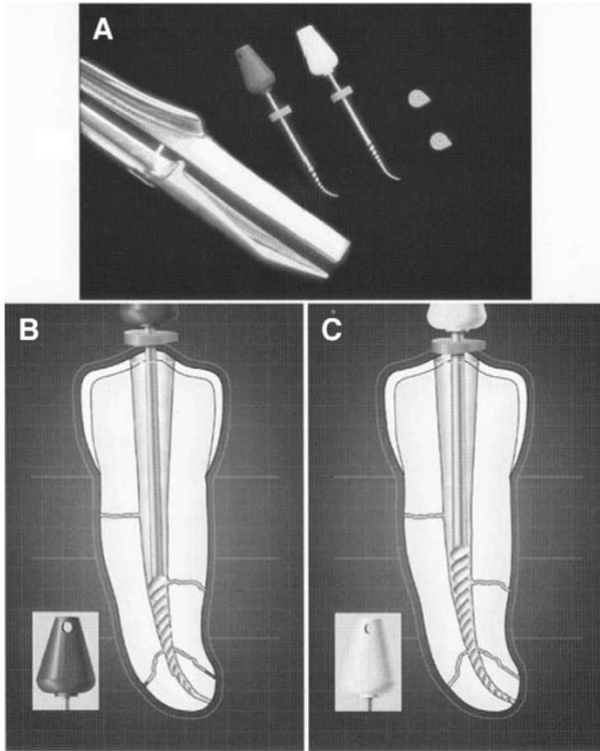


図 4. A) Endo Bender Pliers を使用して GT ロータリーNiTi ファイルをプリカーブさせている。B) 0.10 テーパーの GT ファイルをプリカーブさせ、レッジを迂回させている。C) 0.08 テーパーの GT ファイルを使用してレッジを除去し、管の長さを最大限に形成しています。Cohen S, Burns BC からの許可を得て複製しました。Pathways of the Pulp. 8th ed. 8th ed. St. Louis, MO: Mosby, 2002; 913.2

### 根管充填

- レッジが除去できない場合は、マスターガッタパーチャポイントの装着がレッジに「引っかかる」傾向がある。このような場合、マスターポイントは、根管の曲率をシミュレートするために、あらかじめ湾曲させておく必要がある。
- マスターポイントの上部の端にノッチを設け、術者が作業長と曲率の方向を確認できるようにする。
- ガッタパーチャポイントの先端部分を 70% イソプロピルアルコール溶液に数秒間浸すと、ガッタパーチャポイントの剛性が高まる。これらの手順を踏むことで、試適と根充の両方でマスターポイントの挿入が容易になる。

## 外科的歯内療法

- ・レッジを回避することができない場合、治療の選択肢は、根管貼薬剤を使用するか、歯根端切除術を行うかに限られる。
- ・レッジがあっても、根管貼薬を使用して根尖部を消毒できる場合がある。このようなケースでは、6～12 ヶ月の間に根尖部の X 線透視像が小さくなることで、十分な消毒が行われていることが確認できる。しかし、治癒が見られない場合や症状が改善されない場合には、歯根端切除術が必要となる。歯根周囲手術で歯根の先端部分をどの程度切除すべきかを判断する際には、レッジの存在と位置を考慮すべきである。
- ・歯根端切除術が必要であっても、歯の位置やその他の局所的要因のために現実的でない場合は、抜歯を検討すべきである。多根歯の一根にレッジがある場合、抜歯よりも患部の歯根を切断した方が良い場合がある。このような場合には、患部の歯根を除去し、残りの歯根を残して修復する。
- ・症例によっては意図的再植が行われる。一般的には、非外科的歯内療法が不可能な場合や効果が得られない場合、また、視覚的および／または外科的アクセスが悪い場合、あるいは隣接する解剖学的構造に外科的損傷を与える危険性がある場合には、意図的再植が治療の選択肢となる。

## 予後

- ・レッジは、歯内療法を複雑にし、治療対象の歯の長期的な予後を大きく変える可能性がある。
- ・手術用顕微鏡や超音波機器を使用してバイパスし、レッジを除去または縮小するが、これにより良好な結果が得られる割合は 79%にまで増加する。
- ・根管がレッジを越えられない場合、適切な観察期間の後、さらに評価を行い、根尖手術が必要かどうかを判断する。もし、術前に根尖歯周組織が正常で、レッジが根穿孔に比較的近い位置に形成されていれば、通常、予後は非常に良好であると考えられる。
- ・術前に根尖病変が認められた場合や、レッジが根尖孔からかなり離れた位置に形成された場合には、感染根管の根尖部を洗浄、消毒、充填することができないため、外科的歯内療法が必要となることがある。
- ・根管形成過程の初期に形成された場合には、根尖部は十分に洗浄・消毒されていない可能性があるが、根管形成過程の後期に形成された場合には、根尖部はすでに十分に消毒されており、根尖性歯周炎の治癒の可能性がある。

・患者には、予後、再診の重要性について説明しなければならない。将来、根尖性歯周炎が進行していることを示す臨床症状や X 線写真の変化が認められた場合には、歯内療法の専門医への紹介、再治療、歯根端切除手術、抜歯など必要となる。

報告の考 察
-----------

レッジは、理想的な根管形成・拡大・洗浄・充填を妨げ、歯内療法後の患歯にマイナスの影響を与える可能性がある。よって、レッジ形成の原因を理解し、予防に努力しなければならない。また、適切なアクセスキャビティーや器具操作を行い、また、使用する器具の特性を理解しておく必要がある。

レッジの対処法の理解、レッジが除去できなかった場合の対処法（経過観察するのか、外科的歯内療法等）も理解しておかなければならない。

報告者 東 修平

# Ledge Formation: Review of a Great Challenge in Endodontics

Hamid Jafarzadeh, DDS, MSc,\* and Paul V. Abbott, BDS, MDS, FRACDS (Endo)<sup>†</sup>

## Abstract

Failure to grasp the rationale behind cleaning and shaping concepts can increase the occurrence of needless complications, such as ledges. A ledge is created when the working length can no longer be negotiated and the original pathway of the canal has been lost. Extension of the access cavity to provide unobstructed access to the root canals, precurving and not forcing instruments, using NiTi files, using passive step-back and balanced force techniques, and instrumenting the canal to its full length will all help to prevent ledge formation. Initial negotiation and bypassing the ledge can be achieved using a small file with a distinct curve at the tip, whereas a slight rotation motion of the file combined with a "picking" motion can often help advance the instrument. A review of the literature and a discussion of the options for prevention, recognition and managing the ledge are presented. (*J Endod* 2007; 33:1155–1162)

## Key Words

Bypass, endodontic mishap, ledge

Endodontic mishaps or procedural accidents are unfortunate occurrences that can occur during treatment. Some might be due to inattention to detail, whereas others are unpredictable (1). Failure to grasp the rationale behind cleaning and shaping concepts can increase the occurrence of needless complications such as blockages, ledge formation, apical transportation, and perforations. These have been attributed to inappropriate cleaning and shaping concepts (2).

Among the complications most commonly observed during root canal instrumentation is a deviation from the original canal curvature without communication with the periodontal ligament, resulting in a procedural error termed *ledge formation* or *ledging* (Fig. 1, A). This often results when the operator works the files short of the full canal length, and the canal becomes blocked at that "short point". This might create a ledge, or it might begin to form a new pathway at a tangent to the true pathway of the root canal (3). The presence of a ledge might exclude the possibility of achieving an adequately shaped canal preparation that reaches the ideal working length, and this can result in incomplete instrumentation and disinfection of the root canal system as well as incomplete filling of the canal. The root canal space apical to the ledge is difficult to thoroughly clean and shape; therefore, ledges frequently result in ongoing periapical pathosis after the endodontic treatment. Consequently, there might be a causal relationship between ledge formation and unfavorable endodontic treatment outcomes (2, 4–9).

Occasionally even very skilled and careful clinicians might create a ledge within a root canal when treating teeth with unsuspected aberrations in the anatomy of the canal. Because of the noticeable incidence of ledge formation in endodontic practice and the critical need for its recognition and management, this review aims to address the etiology, associated factors, recognition, prevention, prognosis, and the important considerations in the endodontic management of the ledge.

## Etiology

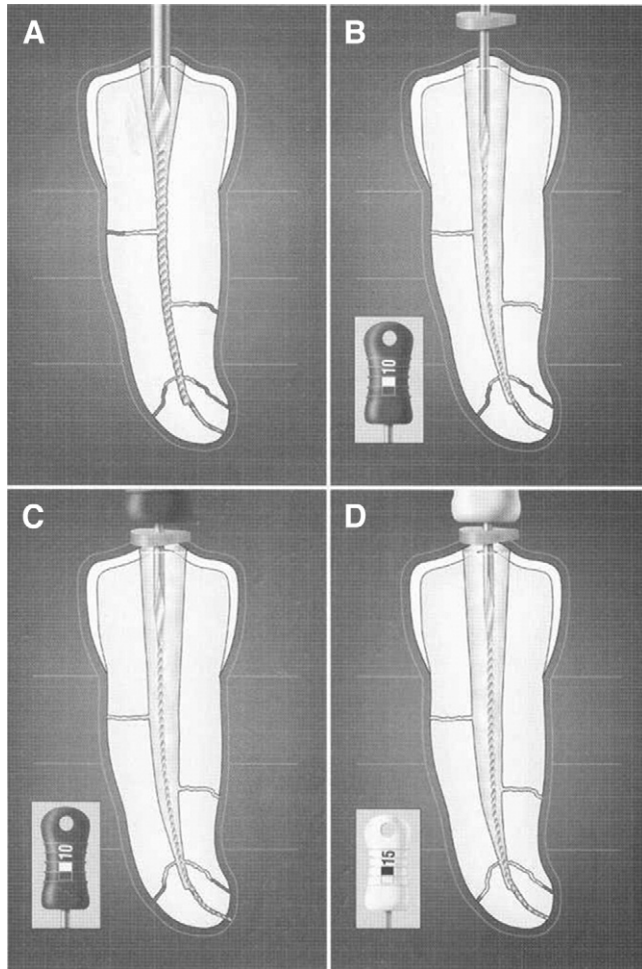
Ledges might be caused by a number of errors during endodontic treatment, such as:

- (1) Not extending the access cavity sufficiently to allow adequate access to the apical part of the root canal (1, 2, 4, 10, 11)
- (2) Complete loss of control of the instrument if the endodontic treatment is attempted via a proximal surface cavity or through a proximal restoration (1)
- (3) Incorrect assessment of the root canal direction (2, 4, 10)
- (4) Erroneous root canal length determination (2, 4, 10)
- (5) Forcing and driving the instrument into the canal (12)
- (6) Using a noncurved stainless steel instrument that is too large for a curved canal (1, 2, 4, 8, 10, 13)
- (7) Failing to use the instruments in sequential order (2, 4, 8, 10)

From the \*Department of Endodontics, Faculty of Dentistry and Dental Research Center, Mashhad University of Medical Sciences, Mashhad, Iran; and <sup>†</sup>School of Dentistry, University of Western Australia, Perth, Australia.

Address requests for reprints to Dr. Hamid Jafarzadeh, Faculty of Dentistry and Dental Research Center, Vakilabad Blvd, Mashhad, Iran. E-mail address: hamid\_j365@yahoo.com  
0099-2399/\$0 - see front matter

Copyright © 2007 by the American Association of Endodontists.  
doi:10.1016/j.joen.2007.07.015



**Figure 1.** (A) An instrument binding throughout its length and not following the canal curvature at the tip of the file. (B) Pre-enlargement of the coronal two thirds of the canal and initial bypassing of the ledge with a precurved No. 10 file that has not yet reached the full length of the canal. (C) The ledge has been bypassed, and the canal has been negotiated to its full length with the No. 10 file. (D) A No. 15 file has been used to bypass the ledge and negotiate the canal to its full length. Reproduced with permission from Cohen S, Burns RC. *Pathways of the Pulp*. 8th ed. St. Louis, MO: 2002;913.<sup>2</sup>

- (8) Rotating the file at the working length (that is, overuse of a reaming action) (8, 12)
- (9) Inadequate irrigation and/or lubrication during instrumentation (11)
- (10) Over-relying on chelating agents (12)
- (11) Attempting to retrieve broken instruments (2, 4, 10)
- (12) Removing root filling materials during endodontic retreatment (2, 4, 10)
- (13) Attempting to prepare calcified root canals (2, 4, 10)
- (14) Inadvertently packing debris in the apical portion of the canal during instrumentation (that is, creating an apical blockage) (2, 11)

**Frequency and Associated Factors**

Very few data are available regarding the frequency of ledge formation and the clinical factors associated with its occurrence. Factors such as the instrumentation technique, root canal curvature, tooth type, and canal location have all been proposed to be associated with ledge formation (3, 4, 6, 7, 14–24) (Tables 1 and 2). Almost all of these studies have indicated that

the curvature of the root canal is the most significant variable affecting the incidence of ledge formation (4, 7, 15, 16).

There is a wide range in the reported incidences of ledge formation, which is likely to be a result of the various associated factors included in each study. Bergenholtz et al (14) concluded that 25% of the root canals in their study that were retreated for technical reasons and 11% that were retreated because of the presence of periapical pathosis were obstructed at the level of the previous root canal filling. Stadler et al (15) reported that the incidence of ledge formation in teeth treated by supervised dental students was 10%. Greene and Krell (7) examined radiographs of cases treated by dental students, and they concluded that 46% of the canals had been ledged. This percentage increased significantly when the curvature of the canal was greater than 20 degrees, and it surpassed the number of canals that were not ledged once the curvature was greater than 30 degrees. Kapalas and Lambriani-dis (4) indicated that 52% of the canals treated by students had been ledged. In contrast, when endodontists did root canal treatment, ledges were formed in 33% of previously untreated canals and 41% in endodontic retreatment cases. Eleftheriadis and Lambriani-dis (16) reported that 25% of the root canals treated by undergraduate dental students had been ledged.

**Recognition**

Recognition of a ledge is the first step in its management; this might be by clinical or radiographic observation. When a ledge is formed, the canal is usually “straightened” at that point. Suddenly the file no longer negotiates the curve but catches on a “dead end”. There might be a loss of normal tactile sensation of the tip of the instrument binding in the lumen of the canal. This feeling is supplanted by that of the instrument point hitting against a solid wall, that is, a loose feeling with no tactile sensation of tensional binding. When ledge formation is suspected, a radiograph of the tooth with the instrument placed at the point of the suspected ledge should provide additional information. The central x-ray beam should be directed perpendicularly through the involved area. If the radiograph shows that the instrument point is directed away from the lumen of the canal, then it is highly likely that there is a ledge, and the subsequent completion of the root canal preparation must include an effort to bypass this ledge (1, 11).

In cases that require endodontic retreatment by removing an existing root canal filling, the possible presence of a ledge should be considered when the existing root canal filling is at least 1 mm shorter than the ideal working length, or if the filling appears to have been placed in a position that is deviated from the natural pathway of the root canal, especially in teeth in which the root canal curves to any significant extent (4, 7, 16).

**Prevention**

The best approach to managing ledges is prevention. If the operator is careful and attentive during the instrumentation process, then the chance for an impediment such as a ledge to develop will be minimized. The endodontic literature provides much information that can help to prevent procedural errors such as ledge formation. It is also true that experience can teach many valuable lessons if one pays attention at all times. Put another way, each operator should learn from his/her own mistakes as well as from those of other people, and this is surely true of endodontic mishaps as well. Treatment evaluation and critical analysis of one’s own work can help prevent future occurrences (1, 9).

The use of accurate preoperative and “working” radiographs to determine the root canal length, copious irrigation, precurved files, and incremental instrumentation will all greatly reduce the chances of ledge

**TABLE 1.** Summary of Factors Reported to be Associated with Ledge Formation

Authors/year	Factors evaluated		Results	Tooth type	Sample size	Method of study
Bergenholtz et al, 1979 (14)	Reason for endodontic retreatment		Technical reasons have higher possibility of ledge formation than presence of periapical pathosis	All teeth	660	Clinical and radiographic re-examination, 2 years after endodontic retreatment
Stadler et al, 1986 (15)	Instrumentation technique		Reaming technique has more important effect in comparison with filing technique	Roots with various degrees of curvature	520	Clinical study of treatment by supervised dental students
	Root canal curvature		Significant variable (curvature $\geq 35$ degrees has main effect on incidence)			
Greene and Krell, 1990 (7)	Tooth number		Significant variable	Maxillary and mandibular molars	171	Radiographic examination of cases treated by third-year dental students
	Canal location		Significant variable			
	Working length		Insignificant variable			
	Master apical file size		Insignificant variable			
	Root canal curvature		Most significant variable (curvature $\geq 20$ degrees has main effect on incidence)			
Nagy et al, 1997 (3)	Root canal morphology		Insignificant variable	Extracted roots (straight, apically curved, or entirely curved canals)	420	Superimposition of buccolingual and mesiodistal radiographs before and after canal preparation
Kapalas and Lambrianidis, 2000 (4)	Undergraduate students	Canal location	Significant variable (MB, ML, and DB canals have higher frequency than D and P canals)	Maxillary and mandibular molars	141	Evaluation based on angled working length radiographs, master cone radiographs, and final radiographs
		Canal curvature Tooth number	Most significant variable Insignificant variable (but mandibular left 2nd molar had highest incidence)			
	Endodontists (treatment cases)	Canal location	Significant variable (MB and DB canals have highest incidence)	Mandibular molars	78	
		Canal curvature Tooth number	Most significant variable Insignificant variable			
	Endodontists (retreatment cases)	Canal location	Insignificant variable	Mandibular molars	25	
		Canal curvature Tooth number	Most significant variable Significant variable			
Eleftheriadis and Lambrianidis, 2005 (16)	Tooth type		Significant variable (higher prevalence in molars than in anterior teeth or premolars)	140 anterior teeth, 156 premolars, 92 molars	388	Evaluation of postoperative radiographs from patient records
	Molar location		Insignificant variable (but mandibular left 2nd molar exhibited highest incidence)			
	Canal location (in molars)		Significant variable (MB, ML and DB canals have highest incidence)			
	Root canal curvature		Most significant variable			

D, distal; DB, distobuccal; MB, mesiobuccal; ML, mesiolingual; P, palatal.

formation occurring (12). Moreover, caution must be used in attempting to recover from a blockage of the canal, especially when it occurs at a curve or bend in the canal direction. An all too common and unfortunate result is the creation of a ledge and/or a lateral perforation in such a situation (1). Some important considerations in prevention of this iatrogenic error are discussed below.

### Preoperative Evaluation

Prevention of ledge formation begins with a thorough examination of the preoperative radiograph for curvatures, canal length, and initial size. Accurate interpretation of these radiographs should be completed before treatment is commenced and before the first instrument is placed in the canal because roots that curve toward or away from the central x-ray beam (that is, toward the buccal or lingual) are much more difficult to assess. Knowledge and awareness of the typical root canal morphology and its variations are imperative at all times throughout endodontic treatment but particularly during the instrumentation procedures (1, 11).

### Technical Procedures

Rapid and significant changes in techniques, instrument design, and the type of metals used to manufacture endodontic instruments have been made during the last few years in an attempt to overcome canal preparation errors (25).

### Access Cavity Preparation and Working Length Determination

Determination of the working length before the cleaning and shaping process is a continuation of the access cavity preparation. An accurate working length measurement is a requirement for endodontic treatment because canal preparation short of the ideal length is a prelude to ledge formation (11). In addition, optimum access to the apical third of the canal cannot be achieved until the canal shaping/enlargement process has been completed.

Severe curvatures in the coronal half of the root canal might predispose to ledge formation. Straight-line access to the orifice of the canal can be achieved through having an appropriate access cavity, but accessibility to the apical third of the canal can only be achieved with adequate flaring of the coronal half of the canal. Longer canals and

**TABLE 2.** Comparison of Instrumentation Techniques and Their Relationships to Ledge Formation: Summary of Reported Studies

Author(s)/year	File systems/ techniques examined	Type of canals/teeth	Highest incidence of ledge formation	Lowest incidence of ledge formation	Sample size	Incidence of ledge formation	Method of study
McKendry et al, 1988 (17)	K-Flex and Flex-R files	Molars	K-Flex file	Flex-R file	127	K-Flex (37%) Flex-R (21%)	Radiographic evaluation by 2 endodontists
Zmener and Marrero, 1992 (18)	Tri-files, Flex-R files, Flexofiles, and K-files	Curved root canals of extracted single-rooted teeth	Flexofile and conventional K-files	Tri-file and Flex-R files	80	0% (Tri-files & Flex-R) 10% (Flexofile) 30% (K-file)	Scanning electron microscope
Nagy et al, 1997 (3)	Traditional and flexible hand instruments, 3 different engine-driven instruments, sonic and ultrasonic instruments	Extracted human teeth in 3 groups (straight canals, apical curve, and curves along entire length of root)	Not stated	Not stated	420	Not stated	Superimposition of buccolingual and mesiodistal radiographs before and after canal preparation
Kapalas and Lambrianidis, 2000 (4)	Step-back technique	Mandibular and maxillary molars	—	—	367* 259†	52%* 33%† (treatment) 41%† (retreatment)	Evaluation based on angled working length radiographs, master cone radiographs, and final radiographs
Namazikah et al, 2000 (6)	SS K-files and Rotary NiTi 0.04 taper files	Extracted maxillary and mandibular first molars	SS K-files	Rotary 0.04 taper files	196	Not stated	Examination of preoperative and postoperative radiographs by postgraduate endodontic students
Calberson et al, 2002 (19)	GT rotary files	Simulated resin root canals with 40- and 60-degree curvature	—	—	38	2.6%	Image superimposition and analysis of preoperative and postoperative pictures
Xu et al, 2004 (20)	ProTaper rotary system and hand files step-back technique	Teeth with curved root canals	Hand files step-back technique	ProTaper	68	0% (ProTaper) 5.8% (hand technique)	Analysis with radiographs before, during, and after operation
Xu et al, 2005 (21)	ProFile, ProTaper, and Hero 642 rotary systems	Teeth with curved root canals	—	—	80	0%	Analysis with radiographs before, during, and after operation
Xu et al, 2005 (22)	Hero 642 rotary system and hand files step-back technique	Molars	Hand files step-back technique	Hero 642	60	0% (Hero 642)	Radiographs before and after treatment
Yoshimine et al, 2005 (23)	ProTaper, K3, and RaCe rotary systems	Simulated S-shaped canals in clear resin blocks	ProTaper	K3 and RaCe	30	Not stated	Comparison of preoperative and postoperative images under stereomicroscope
Jahan et al, 2006 (24)	Er:Cr:YSGG laser and conventional canal preparation	Extracted human permanent mandibular molars (straight and curved roots)	No difference	No difference	40	Not stated	Morphologic study

\*Root canals prepared by students.

†Root canals prepared by endodontists.

canals of small diameter are most prone to ledging compared with shorter and larger diameter canals. Careful attention to maintaining the pathway is required to prevent ledge formation (2, 11).

### Irrigation/Lubrication/Chelating Agents

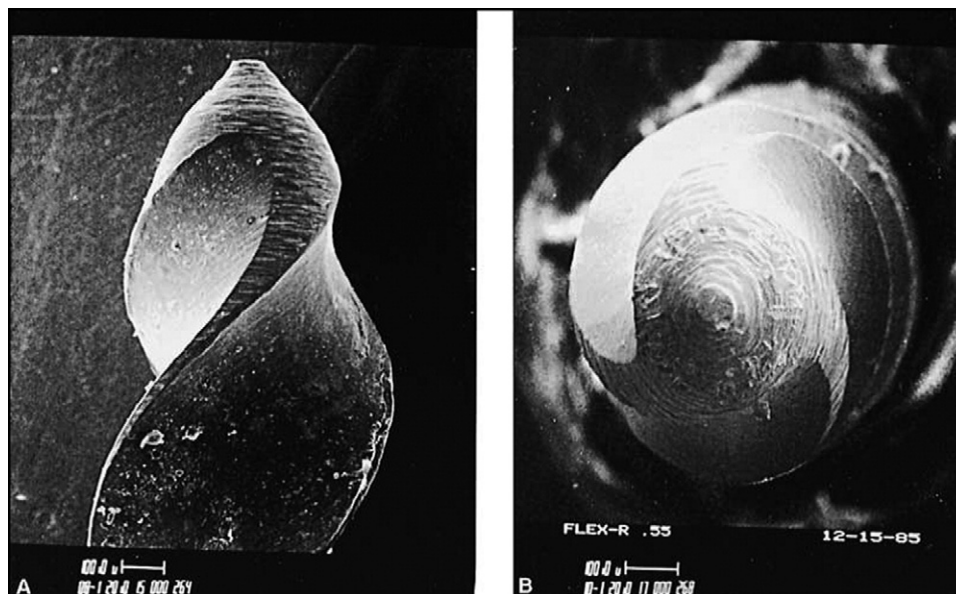
Frequent recapitulation and irrigation, along with the use of lubricants, are mandatory during root canal instrumentation. Sodium hypochlorite might be used initially for hemorrhage control, antibacterial action, lubrication, and removal of organic debris. In addition, silicone, glycerin, and wax-based lubricants are commercially available for canal lubrication. Because these materials are viscous, they can be carried into the apical regions of the canal with the file. Enhanced lubrication permits easier file insertion, reduced stress to the file, and assists with removal of debris. The lubricant is easily removed with sodium hypochlorite irrigation (11).

Chelating agents such as ethylenediaminetetraacetic acid should be used with caution when one is attempting to negotiate curved canals. Because these materials soften the dentin walls, a ledge can be begun anywhere along the root canal wall if excessive instrumentation pressure is used (1, 8). However, when used appropriately, they can be

valuable aids to instrumentation and disinfection by removing inorganic debris and the smear layer (26).

### Instrumentation Techniques

Passive step-back and balanced force techniques are two beneficial methods of canal preparation that reduce the chances of ledge formation (1, 11). Moreover, it has been proposed that an advantage of the step-back technique is that this method tends to minimize procedural errors such as transportation and ledge formation (27). Each file must be worked inside the canal until it is loose before a larger size is used. Also, files must be used sequentially and must not bind excessively in the canal. If binding is present, the operator should immediately return to a smaller file size and use circumferential filing to remove any irregularities or steps that might have begun to form during the placement of the larger-sized instrument. The effective use of circumferential filing, especially with Hedström files, will ensure smoothness of the canal walls and flaring toward the coronal end of the canal, which will help to prevent the formation of ledges (8, 11). Also, severe apical curvatures require the proper sequential use of root canal instruments to maintain a pathway to the full working length of the canal (2, 11).



**Figure 2.** A Flex-R-file with noncutting tip. (A) Rounded tip. (B) “End-on” or “nose” view of the noncutting tip demonstrates its shape, which leads to less gouging of the root canal wall and less likelihood of ledge formation occurring. Reproduced with permission from Ingle JI, Bakland LK. *Endodontics*. 5th ed. London: B.C. Decker Inc, 2002;483.<sup>1</sup>

Precurving the instruments and not forcing them into the canal is one of the most important considerations in the prevention of ledge formation (1). When files have been precurved, the original canal shape of the canal is more easily maintained, and a reaming action must not be used (12). Failure to precurve the instruments and forcing large files into curved canals are perhaps the most common reasons why the ledge occurs. The use of instruments with noncutting tips and NiTi files has been shown to be very beneficial in maintaining root canal curvatures (1).

It is also worth noting that root canal preparation by using laser irradiation techniques might result in more ledge formation than conventional hand techniques with K-type files (28).

### Instrument Modifications

The incidence of ledge formation with the use of flexible files (such as NiTi files) is less than when conventional hand stainless steel K-type files are used (11, 29). Although NiTi rotary instruments have reduced clinical mishaps such as blockages, ledges, perforations, and perforations (2), Parashos and Messer (30) reported that their survey about the use of rotary instruments by Australian dentists indicated that one of the main reasons for dentists not using these instruments is that they are concerned about the formation of ledges.

Although abrasive tips might be helpful when penetrating canals smaller than the file (2), the metallic memory of stainless steel to return to a straight position increases the tendency to transport or ledge a canal and eventually to perforate curved canals. If the tip angle is reduced, the file tends to stay centered within the original canal space and will cut all sides (that is, circumferentially) more evenly (13). Hence, the modified-tip files tend to maintain the original canal curvature better and more frequently than unmodified-tip files (31). The modified-tip files have been marketed as Flex-R files (Moyco/Union Broach, Miller Dental, Bethpage, NY), Control Safe files (Dentsply/Maillefer, Tulsa, OK), Anti-Ledging Tip files (Brasseler, Savannah, GA), and Safety Hedström files (Sybron Endo/Kerr, Orange, CA) (1). The concept of use of these files is that the rounded tip does not cut into the wall but will slip alongside it (Fig. 2) (1, 32).

The Flex-R file designed by Roane (1985) was the first to use a noncutting tip to help avoid ledge formation in curved canals (33). This

design incorporated a guiding plane and removed the transition angles inherent on the tip of standard K-type files. Lacking a sharp transition angle, the Flex-R files will follow the canal, and they are prevented from gouging into the walls. The tip design causes a Flex-R file to hug the inside of a curve and prevent the tip from engaging the external wall of the curve (1). Some researchers have reported that during crown-down rotational instrumentation techniques, biconical file tips (such as the Flex-R file) maintain the original canal curvature better and more frequently than do conical (such as the Mor-Flex files) file tips and those with pyramidal file tips (such as the Flex-O files) (34).


Other useful instruments are C+ Files (Dentsply/Maillefer, Johnson City, TN). They have stronger buckling resistance compared with K-files, which allows easier location of the canal orifices and easier access to the apical third of the canal. The pyramid-shaped tip facilitates insertion during negotiation of the canal, and the square cross-section provides better resistance to distortion. The polished surface of the C+ File also allows smoother insertion of the instrument in the canal. C+ Files are available in 3 lengths (18 mm, 21 mm, and 25 mm) and 3 sizes (8, 10, and 15) (35, 36).

It should be noted that in tightly curved canals where it is extremely difficult to advance from a No. 10 file to a No. 15 file, “half-step” files that are commercially available as FlexoFile Golden Mediums (LD; Caulk/Dentsply, Milford, DE) can assist in instrumentation. Subsequent filing with these modified files will open the canal some more and render it more suitable for negotiation with the next available standard size, that is, a No. 15 file. In fact, such files are designed to assist canal negotiation and provide a more gradual increase in size (8).

### Endodontic Management

It would be of immense value if operators were able to correct a ledge. The correction of a ledge might be accomplished in one of several ways, depending on the extent of the procedural accident. Relocating and renegotiating the original canal can be a problem, and bypassing or removing the ledge is difficult, even if the canal can be renegotiated to its ideal working length. In some instances, lateral perforations might occur when the ledge is created during initial instrumentation or as a “strip perforation” on the





**Figure 3.** A distinct curve at the tip of the file.

concave side of the curvature of the root as the canal is straightened out. Unfortunately, perforations might sometimes cause such extensive damage to the tooth that it needs to be extracted (1, 11).

A ledge created by a No. 25 or 30 file is much more difficult to bypass than one created by a smaller file because the shelf created by the larger instrument is more likely to prevent penetration beyond the ledge. The smaller the width of the shelf, the less likely it is that the instrument will be prevented from reaching full canal length. In any case, early recognition will facilitate the management of such an error (8). Some important considerations in the management of the ledge are discussed below.

### Initial Negotiation/Bypassing the Ledge

The most critical requirements for bypassing the ledge are determination, perseverance, and patience (2). Generally when attempting to bypass a ledge, the shortest file that can reach the ideal working length should be selected. Shorter instruments provide more stiffness and allow the clinician's fingers to be placed closer to the tip of the instrument, which results in greater tactile sensation and thereby helps to provide more control over the instrument. It is important to appreciate that the root canals are frequently more curved than the roots that contain them. Hence, a small file (such as a No. 10 or 15 file) with a distinct curve at the tip (that is, in the apical 2 to 3 mm) (Fig. 3) should be used initially to explore the canal to the apical foramen (1, 2, 11). The curved tip should be pointed toward the wall opposite the ledge. Tear-shaped rubber stoppers on the file are valuable in this situation because the tear can be pointed in the same direction as the curve placed in the instrument (1). A slight rotation motion of the file combined with a "picking" motion can often help advance the instrument and gently slide it to the full working length of the canal (1, 11). Whenever resistance to negotiation is met, the file should be retracted slightly, rotated, and then advanced again, with the precurved tip facing in a different direction. This action should be repeated until the file bypasses the ledge (1). If this technique is unsuccessful, the operator should pre-enlarge the canal coronal to the ledge with thorough irrigation and then slightly over-curve a small file to facilitate bypassing the ledge and negotiating the canal to its full working length. With the picking motion, the operator should continuously reorient the file by carefully watching the unidirectional (tear-shaped) rubber stopper. Reorientation of the stopper will automatically redirect the apical aspect of the precurved file, with the aim of negotiating the apical part of the canal (2, 11).

Application of the C+ Files (Dentsply/Maillefer) that have been introduced for the initial instrumentation of the root canal can be very helpful when attempting to bypass ledges. They are reported to be better

for negotiating calcifications and to provide better tactile feel. Their flexibility can help to bypass the ledge (35, 36).

Ledges that develop on the canal wall allow space for deflection of a file. Nickel-titanium instruments are very flexible; therefore, they might curve back on themselves, so they should not be used to bypass ledges. Once the canal has been fully negotiated with at least a stainless steel No. 15 hand file, or if the ledge has been bypassed and removed, then rotary NiTi instruments can be used for further canal enlargement (1).

### Optional Procedures After Bypassing the Ledge (Completion of the Treatment)

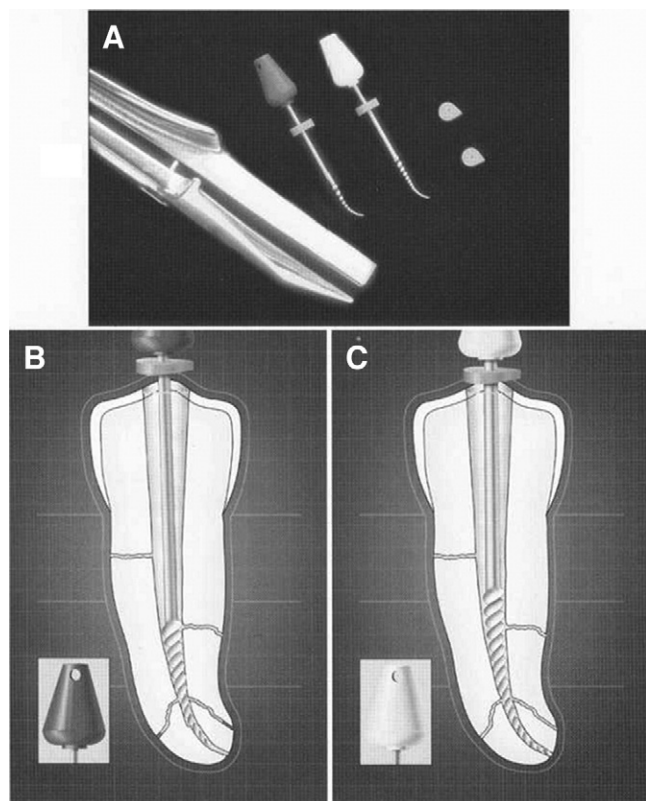
If the exploring instrument can be placed to the full working length, an apex locator might be useful in determining whether the apical foramen has been reached, and then a confirmatory periapical radiograph should be taken to confirm the working length. Subsequent files should be used in the same manner as the exploring file to maintain the true pathway of the canal to its apical foramen. Once the ledge has been bypassed, it is important that each subsequent file is placed to the full working length of the root canal before being used in a filing action. If it is placed short of ideal length at any time, then the ledge might become larger, or a new ledge might be formed (1). Completion of the canal preparation can best be accomplished by following one of the two following recommendations.

#### Recommendation 1

Once the tip of the file can be placed apical to the ledge, it should be moved in and out of the canal with a filing motion and occasionally very short push-pull movements, with emphasis on staying apical to the defect (2, 11) (Fig. 1, B–D). Use of a lubricant and frequent irrigation to remove dentin chips will help to prevent blockages. Operators should use files that have been precurved in the apical portion of the file. Short file strokes, with the instrument pressed against the canal wall where the ledge is located (1), will help to remove the edge of the ledge; typically the ledge will be located on the outer wall of the curved part of the root canal. When the file moves freely, slightly longer push-pull strokes can be used to reduce the size of the ledge and to confirm the presence or absence of internal canal irregularities. If the file is sliding easily in the canal, then it should be turned clockwise on withdrawal because this motion tends to straighten the apical one third of stainless steel files and allows them to rasp, reduce, smooth, or eliminate the ledge. During these procedures, the operator should try to keep the file within the root canal, that is, coronal to the apical foramen, so that the file can be handled delicately, and the apical foramen can be kept as small as practical (2). Moreover, the canal should be constantly irrigated to wash out dentin filings. The tip of the file must be checked repeatedly to be certain that the curve is maintained. If the instrument is allowed to straighten, it will again catch on the ledge, and repeated filing will lead to enlargement of the ledge or, worse, a perforation of the canal wall.

#### Recommendation 2

An instrument that might assist with ledge management is the Greater Taper (GT) NiTi hand files (Dentsply/Tulsa Dental). The major advantage of using GT hand files to remove a ledge is that their tip diameters are 0.20 mm, their maximum flute diameter is 1.00 mm, and their tapers are 3–6 times the conventional 0.02 tapered files. One single GT hand instrument contains the equivalent of up to 13 ISO-tapered file sizes. However, the GT hand files should not be introduced into the canal until after the ledge has been bypassed, and the canal has been negotiated to its full working length. Bypassing the ledge and negotiating the canal up to a No. 15 and, if necessary, a No. 20 stainless steel hand file creates a "pilot hole" or pathway that the tip of the GT hand file can then follow. To move the



**Figure 4.** (A) The Endo Bender Pliers have been used to precurve GT rotary NiTi files. (B) A precurved 0.10 tapered GT file has been placed to bypass the ledge. (C) A precurved 0.08 tapered GT file has been used to eliminate the ledge and to prepare the canal to its full length. Reproduced with permission from Cohen S, Burns BC. *Pathways of the Pulp*. 8th ed. St. Louis, MO: Mosby, 2002;913.<sup>2</sup>

apical part of a GT hand file past a ledge, the instrument must first be precurved with an appropriate instrument such as the Endo Bender Pliers (Analytic Endodontics, Orange, CA) (Fig. 4, A). The method of precurving a NiTi hand instrument is to first securely grasp the working end of the GT file between the jaws of the file Bender Pliers; the handle is then pulled through a radius of between 180 to 270 degrees. A tear-shaped rubber stopper can then be placed on the instrument and turned to indicate the direction of the apical curve of the file. GT hand files should be used in a crown-down manner, graduating from larger files to smaller files. An appropriately tapered GT hand file should be carried into the canal with the rubber stopper oriented so that the instrument's precurved end can bypass the ledge and move apical to it (Fig. 4, B). Depending on the canal's morphology, this GT hand file might be worked to the full canal length, or a smaller tapered GT hand file might be selected (Fig. 4, C) and used in a similar manner. After the use of the GT hand files, the No. 10 or 15 stainless steel hand file should be guided down the canal to check whether the ledge has been either reduced or eliminated (2).

Ultimately the operator must decide (on the basis of the preoperative radiographs, root bulk, and his/her own experience) whether to continue shaping procedures in the hope of eliminating the ledge completely or whether to abort the procedure if it is deemed that continued efforts will weaken or perforate the root. Operators should remember that not all ledges can, or should, be removed, and they must assess the risks versus the benefits while also making every possible effort to preserve as much dentin as possible (2).

### Root Canal Filling

Once a ledge has been created, even if it can be initially bypassed, the root canal filling materials tend to "catch" on the ledge; hence, complete removal or reduction of the ledge will facilitate the root canal filling procedure (11).

If the ledge cannot be removed, then fitting the master gutta-percha point can be challenging. In these cases, the master point should be precurved to simulate the curvature of the canal. A notch can be placed on the coronal end of the master point so that the clinician can identify the working length and the direction of the curvature. The rigidity of the gutta-percha point will be increased if the apical portion is dipped in a solution of 70% isopropyl alcohol for a few seconds. These steps will facilitate the placement of the master point during both the trial fitting and the root filling procedures (2).

If the ledge cannot be bypassed, then the root canal system might be able to be filled by using thermoplasticized gutta-percha and a thin mix of the root canal sealer (8).

### Endodontic Surgery

If a ledge cannot be bypassed, then the treatment options become limited to the use of intracanal medicaments or periapical surgery with retrograde endodontic treatment.

In some cases with ledges, the apical portion of the canal might still be able to be disinfected by using intracanal medicaments. In these cases, adequate disinfection can be assessed radiographically during a period of 6–12 months by a reduction in the size of the periapical radiolucency. However, if healing does not occur or if symptoms cannot be resolved, then periapical surgery will be indicated. The presence and location of the ledge are factors that should be considered when determining how much of the apical portion of the root should be resected during the periapical surgery (1).

If periapical surgery is needed but impractical because of the tooth position or other local factors, an extraction should be considered. If there is a ledge in one root of a multi-rooted tooth, then root amputation of the affected root might be preferable to extraction. In such a case, the affected root is removed, and the remaining root(s) are retained and restored to prevent the need for a fixed or removable prosthesis to replace the entire tooth (12).

Another treatment option in some cases is intentional replantation. It is generally accepted that intentional replantation might be a treatment alternative when nonsurgical endodontic treatment is either impossible or has not been successful, and periradicular surgery is not advisable because of poor visual and/or surgical access to the area or where there is a danger of surgical damage to adjacent anatomic structures (1). Dryden and Arens (37) proposed that intentional replantation can be the treatment of choice when nonsurgical treatment and/or retreatment are not feasible because of impassable ledges.

### Prognosis

Ledges complicate endodontic treatment, and they might significantly alter the long-term prognosis for the tooth being treated. Dentists should recognize this potential problem and have the ability to manage them. They should also factor them into their decisions regarding the tooth's prognosis, including the possibility that the patient should be referred to a specialist endodontist for further management (2). Specialist endodontists have advanced training and experience in managing such problems; therefore, they are more likely to obtain a favorable outcome of the treatment. Many endodontists will also use an operating microscope and ultrasonic instruments to bypass and remove or reduce the ledge, which can increase the number of favorable outcomes to 79% (38).

If the canal cannot be negotiated beyond a ledge, then the cleaning, shaping, disinfection, and filling of the root canal system can only be performed at the new (that is, shortened) length where the ledge has formed (11). After a suitable observation period, further evaluation will determine whether periapical surgery is necessary. If the periapical tissue was normal preoperatively and if the ledge formed relatively close to the apical foramen, then the prognosis is usually considered to be reasonably favorable. However, when preoperative periapical radiolucency is present (indicating an infected root canal system) or when the ledge forms well short of the apical foramen, then periapical surgery might be required because the apical portion of the infected root canal system cannot be predictably cleaned, disinfected, and filled (12).

Consequently, unfavorable outcomes of endodontic treatment associated with ledges depend on the amount of debris and bacteria left in the untreated apical portion of the canal. The amount will depend on when the ledge was created during the instrumentation process, that is, if it formed early in the process, then the apical portion of the canal might not have been cleaned and disinfected to any extent, whereas if the ledge had formed late in the process, then the apical portion might have already been disinfected sufficiently to allow periapical healing to occur. The patient must be informed about the prognosis, the importance of the recall examination, and what signs or symptoms indicate an unfavorable outcome. The future appearance of symptoms, clinical signs, or radiographic changes indicating ongoing periapical disease requires further management such as referral to a specialist endodontist, endodontic retreatment, apical surgery, or extraction of the tooth (11).

**References**

1. Ingle JI, Bakland LK. Endodontics. 5th ed. London: BC Decker Inc, 2002;412,482–9, 525–38, 695, 729, 769, 776–85.
2. Cohen S, Burns RC. Pathways of the pulp. 8th ed. St Louis: Mosby, 2002;94, 242–52, 530, 870, 910–6.
3. Nagy CD, Bartha K, Bernath M, Verdes E, Szabo J. The effect of root canal morphology on canal shape following instrumentation using different techniques. *Int Endod J* 1997;30:133–40.
4. Kapalas A, Lambrianidis T. Factors associated with root canal ledging during instrumentation. *Endod Dent Traumatol* 2000;16:229–31.
5. Harty FJ, Parkins BJ, Wengraf AM. Success rate in root canal therapy: a retrospective study of conventional cases. *Br Dent J* 1970;128:65–70.
6. Namazikhah MS, Mokhlis HR, Alasmakh K. Comparison between a hand stainless-steel K file and a rotary NiTi 0.04 taper. *J Calif Dent Assoc* 2000;28:421–6.
7. Greene KJ, Krell KV. Clinical factors associated with ledged canals in maxillary and mandibular molars. *Oral Surg Oral Med Oral Pathol* 1990;70:490–7.
8. Gutmann JL, Dumsha TC, Lovdahl PE, Hovland EJ. Problem solving in endodontics. 3rd ed. St Louis: Mosby, 1997:96–100, 117.
9. Cohen S, Hargreaves KM. Pathways of the pulp. 9th ed. St Louis: Mosby, 2006:992–4.
10. Lambrianidis T. Ledge formation. In: Iatrogenic complications during endodontic treatment. Thessaloniki, Greece: Univ Studio Pr, 1996.
11. Walton RE, Torabinejad M. Principles and practice of endodontics. 3rd ed. Philadelphia: WB Saunders, 2002:184, 222–3, 319–20.
12. Weine F. Endodontic therapy. 5th ed. St Louis: Mosby, 1996:324–30, 545–7.

13. Powell SE, Wong PD, Simon JH. A comparison of the effect of modified and non-modified instrument tips on apical canal configuration: part II. *J Endod* 1988;14:224–8.
14. Bergenholtz G, Lekholm U, Milthorn R, Heden G, Odesjo B, Engström B. Retreatment of endodontic fillings. *Scand J Dent Res* 1979;87:217–24.
15. Stadler LE, Wennberg A, Ölgart L. Instrumentation of the curved root canal using filing or reaming technique—a clinical study of technical complications. *Swed Dent J* 1986;10:37–43.
16. Eleftheriadis GI, Lambrianidis TP. Technical quality of root canal treatment and detection of iatrogenic errors in an undergraduate dental clinic. *Int Endod J* 2005;38:725–34.
17. McKendry DJ, Krell KV, McKendry LL. Clinical incidence of canal ledging with a new endodontic file (abstract). *J Endod* 1988;14:194–5.
18. Zmener O, Marrero G. Effectiveness of different endodontic files for preparing curved root canals: a scanning electron microscopic study. *Endod Dent Traumatol* 1992;8:99–103.
19. Calberson FL, Deroose CA, Hommez GM, Raes H, De Moor RJ. Shaping ability of GT™ rotary files in simulated resin root canals. *Int Endod J* 2002;35:607–14.
20. Xu Q, Fan B, Fan MW, Bian Z. Clinical evaluation of ProTaper NiTi rotary instruments in management of curved root canals. *Zhonghua Kou Qiang Yi Xue Za Zhi* 2004;39:136–8.
21. Xu Q, Fan MW, Fan B, Ling JQ, Chen H, Wei X. Clinical evaluation of three nickel-titanium rotary instruments in preparation of curved root canals. *Hua Xi Kou Qiang Yi Xue Za Zhi* 2005;23:286–8, 291.
22. Xu Q, Lin JQ, Chen H, Wei X. Clinical evaluation of Nickel-titanium rotary instruments Hero 642 in root canal preparation. *Shanghai Kou Qiang Yi Xue* 2005;14:2–5.
23. Yoshimine Y, Ono M, Akamine A. The shaping effects of three nickel-titanium rotary instruments in simulated S-shaped canals. *J Endod* 2005;31:373–5.
24. Jahan KM, Hossain M, Nakamura Y, Yoshishige Y, Kinoshita J, Matsumoto K. An assessment following root canal preparation by Er,Cr:YSGG laser irradiation in straight and curved roots, in vitro. *Lasers Med Sci* 2006;21:229–34.
25. Himel VT, Levitan ME. Use of nickel titanium instruments for cleaning and shaping root canal systems. *Tex Dent J* 2003;120:262–8.
26. Abbott PV, Heijkoop PS, Cardaci SC, Hume WR, Heithersay GS. An SEM study of the effects of different irrigation sequences and ultrasonics. *Int Endod J* 1991;24:308–16.
27. Walton RE. Current concepts of canal preparation. *Dent Clin North Am* 1992;36:309–26.
28. Ali MN, Hossain M, Nakamura Y, Matsuoka E, Kinoshita J, Matsumoto K. Efficacy of root canal preparation by Er,Cr:YSGG laser irradiation with crown-down technique in vitro. *Photomed Laser Surg* 2005;23:196–201.
29. Zmener O, Balbachan L. Effectiveness of nickel-titanium files for preparing curved root canals. *Endod Dent Traumatol* 1995;11:121–3.
30. Parashos P, Messer HH. Questionnaire survey on the use of rotary nickel-titanium endodontic instruments by Australian dentists. *Int Endod J* 2004;37:249–59.
31. Sabala CL, Roane JB, Southard LZ. Instrumentation of curved canals using a modified tipped instrument: a comparison study. *J Endod* 1988;14:59–64.
32. Ingle JI. PDQ endodontics. London: BC Decker Inc, 2005:220–1.
33. Beer R, Baumann MA, Kim S. Color atlas of dental medicine: endodontology. Stuttgart: Thieme, 2000:61.
34. Ponce de Leon Del Bello T, Wang N, Roane JB. Crown-down tip design and shaping. *J Endod* 2003;29:513–8.
35. Dentsply United Kingdom. C+ Files. Available at: <http://www.dentsply.co.uk/products/endodontics/c+files.html> Accessed July 2, 2007.
36. Allen MJ, Glickman GN, Griggs JA. Comparative analysis of endodontic pathfinders. *J Endod* 2007;33:723–6.
37. Dryden JA, Arens DE. Intentional replantation: a viable alternative for selected cases. *Dent Clin North Am* 1994;38:325–53.
38. Ling JQ, Wei X, Gao Y. Evaluation of the use of dental operating microscope and ultrasonic instruments in the management of blocked canals. *Zhonghua Kou Qiang Yi Xue Za Zhi* 2003;38:324–6.